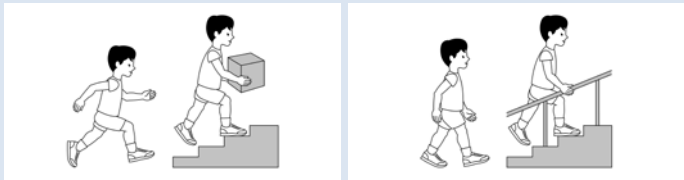






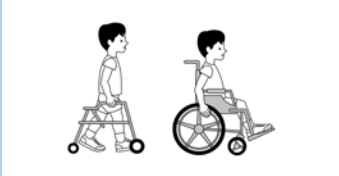













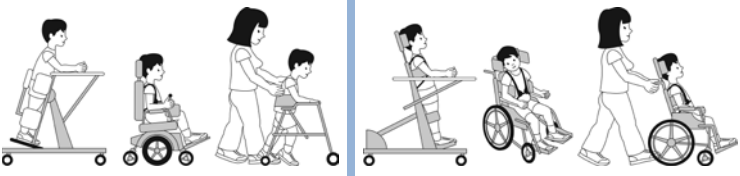





















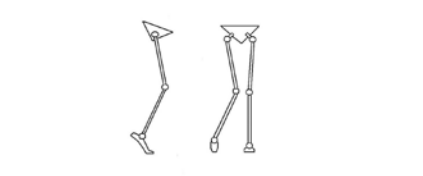












British Columbia Consensus on Hip Surveillance for Children with Cerebral Palsy¹

QUICK GUIDE

Classification	Age in Years										
	ID	2	2.5	3	3.5	4	4.5	5	5.5	6	Continue Until Bones Stop Growing (on X-ray)
 GMFCS I ^{2,3} GMFCS II ^{2,3}								 			
 GMFCS III ^{2,3}		 		 		 		 		 	  Every year Every 2 years
 GMFCS IV ^{2,3} GMFCS V ^{2,3}		 	 	 	 	 	 	 	 	 	  Every year Every year
 Group IV Hemiplegic Gait ^{4,5}								 		 	  Every year Every year

Legend: GMFCS: Gross Motor Function Classification System²

ID: Identification/Diagnosis of cerebral palsy

Group IV Hemiplegic Gait: Child walks with one hip turned and pulled inward⁴



Clinical Exam



X-Ray

References:

1. BC Hip Surveillance Planning Committee. British Columbia Consensus Statement on Hip Surveillance for Children with Cerebral Palsy. Child Health BC, Vancouver, BC, Canada. 2012.
2. Palisano R et al. Content validity of the expanded and revised Gross Motor Function Classification System. *Dev Med Child Neurol.* 2008;50:744-50.
3. Illustrations Version 2. Reid B, Willoughby K, Harvey A, Graham HK. The Royal Children's Hospital, Melbourne, Australia.
4. Winters TF, Gage JR, Hicks R. Gait patterns in spastic hemiplegia in children and young adults. *J Bone Joint Surg (Am).* 1987;69:437-441.
5. Illustrations printed with permission of IOS Press and The Royal Children's Hospital, Melbourne, Australia.