

**BC Children's Hospital
Division of Pediatric Emergency Medicine
Clinical Practice Guidelines**

**INGESTED
FOREIGN BODIES IN
CHILDREN**

AUTHORS:

Navid Dehghani, MD, FRCPC

Division of Pediatric Emergency Medicine
Department of Pediatrics,
University of British Columbia
BC Children's Hospital
4480 Oak Street
Vancouver, BC V6H 3V4
Ndehghani@cw.bc.ca

Jeffrey Ludemann, MDCM, FRCSC

Division of Pediatric Otolaryngology
Department of Surgery,
University of British Columbia
BC Children's Hospital
4480 Oak Street
Vancouver, BC V6H 3V4
jludemann@cw.bc.ca

Erik Skarsgard

Division of Pediatric Surgery
Department of Surgery, University of
British Columbia
BC Children's Hospital
4480 Oak Street,
Vancouver, BC V6H 3V4
eskarsgard@cw.bc.ca

DIVISION OF PEDIATRIC EMERGENCY MEDICINE:

Ran D. Goldman, MD

Division Head and Medical Director
Division of Pediatric Emergency Medicine
BC Children's Hospital
rgoldman@cw.bc.ca

CLINICAL PRACTICE GUIDELINE TASK FORCE:

CHAIRMAN:

Paul Korn, MD FRCP(C)

Clinical Associate Professor
Head, Division, General Pediatrics
Department of Pediatrics, UBC
pkorn@cw.bc.ca

MEMBERS:

TBD

CREATED:

May, 2007

LAST UPDATED:

September, 2007

FIGURES:

2

BACKGROUND:

Foreign body ingestions occur more frequently than foreign body aspirations in children. Most ingested objects pass through the gut spontaneously. Some times, sharp or large objects lodge in the narrow parts of the Gastrointestinal (GI) tract, commonly the esophagus, necessitating endoscopic removal. In contrast to adults who ingest and impact mostly organic objects, children tend to ingest inorganic objects more commonly.

Children usually swallow smooth rounded objects rather than sharp objects. Coins make up the majority of ingested objects in children. Inert rounded objects pass more easily through the GI tract than caustic or sharp objects. However, one must be mindful of the fact that disc batteries are also rounded and are very corrosive to the esophagus.

The narrowest area within the GI tract is the esophagus. Therefore, the commonest site of foreign body impaction is the esophagus. An esophageal foreign body may lodge in three distinct sites: thoracic inlet, aortic arch area, and the gastroesophageal (GE) junction. The commonest site of impaction is in the thoracic inlet followed by the GE junction and then the aortic arch.

Once the object passes into the stomach, the chance of lodgment and impaction is very low. Rarely, sharp or large objects lodge in the pylorus, duodenum, cecum, appendix, rectum, or a location of congenital or acquired narrowing within the GI tract.

PATHOPHYSIOLOGY:

Pathophysiologic considerations for ingested foreign bodies include narrow anatomical sites within the GI tract, the physical characteristics of the foreign body (size, shape, and composition), and the body's reaction to the foreign body. For example, a disc battery may lodge in the narrowest part of the esophagus (the thoracic inlet), erode the esophageal wall, and cause tracheal edema and tracheo-esophageal fistulization and mediastinitis due to its electrical current and lye leak.

EVALUATION:

Esophageal foreign bodies can produce symptoms of dysphagia, refusal to eat, anatomical foreign body localization (in older children), drooling, coughing, stridor, vomiting, gagging, or regurgitation. However, many children with esophageal foreign bodies are asymptomatic. Distal foreign bodies produce less specific symptoms ranging from abdominal pain, vomiting, distension, altered bowel movements, melena, or hematochezia.

The radiographic investigation used in our institution is a 'foreign body series' which is a combination of a soft-tissue lateral neck and a 'wide' chest radiograph including the oropharynx, chest, and abdomen. Classically, partially-obstructive laryngeal foreign bodies are oriented sagittally at the level of vocal cords while esophageal foreign bodies are oriented coronally.

Lateral radiographs are some times used to rule out multiple coins or help differentiated disc batteries from coins (FIGURE 2).

In addition, handheld metal detectors are some times used to monitor the progression of a metallic foreign body as it traverses through the GI tract. The advantage of course is less radiation to the child.

Diagnosis of radiolucent GI foreign bodies requires endoscopic evaluation or contrast radiography.

TREATMENT:

If required, rigid endoscopic removal under general anesthesia with oral endotracheal intubation is the commonest modality used to retrieve esophageal foreign bodies. There is no pediatric evidence that medications such as glucagon help the passage of esophageal foreign bodies distally.

For foreign bodies distal to the esophagus, surgical removal via laparotomy is required only in rare cases where a foreign body cannot be retrieved endoscopically; or when a complication such as perforation or obstruction has arisen; or in exceptional cases where sharp or large objects do not demonstrate transit progression for weeks.

COMPLICATIONS:

Esophageal perforation, mediastinitis, tracheo-esophageal fistula formation, and pneumomediastinum are rare complications of esophageal foreign bodies. Complications of distal bowel impaction are much less common and include rupture of hollow viscera and hemorrhage, peritonitis, bowel obstruction, abscess formation, and inflammatory tumors.

SPECIAL CIRCUMSTANCES:

Large esophageal foreign bodies such as a marble can impinge on the airway and cause stridor (typically biphasic). These foreign bodies require urgent removal. Sharp esophageal foreign bodies such as a needle, pin, or hairclip could perforate the esophagus leading to pneumomediastinum. Therefore these objects are removed urgently. Rarely, esophageal foreign bodies, especially coins, are sagittally-oriented. This can encroach on the trachea causing biphasic stridor and therefore requires urgent removal. Presence of pneumomediastinum in the context of an esophageal foreign body implicates esophageal perforation and is another indication for urgent removal of the foreign body.

Disc battery ingestions have traditionally been feared in children as they could cause corrosive injury. A disc battery is removed endoscopically on an urgent basis if it is found to be in the esophagus. In our institution, the removal of an esophageal disc battery belongs to a Class I level of urgency (removal scheduled even if the stomach is full). When a metallic round object is noted radiographically in the esophagus, the clinician must inquire parents about the possibility of exposure to disc batteries and must look for signs of a disc battery on the radiograph. It is imperative to differentiate between coins and disc batteries when evaluating the radiograph of a

foreign body. Disc batteries, like coins, are usually oriented coronally in the esophagus. Subtle radiographic signs of most (not all) disc batteries include a double contour on the Anterior-Posterior (AP) view (FIGURE 1) and shouldering on the lateral view (FIGURE 2). Recent studies suggest that most disc battery ingestion past the esophagus have a benign course with only sporadic reports of systemic absorption. No treatment is therefore required if a disc battery has reached the stomach.

Magnet ingestions cause no systemic toxicity. However, if more than one magnet is ingested, or if a magnet is swallowed with a piece of metal, then there is a higher risk of complications due to impaction of bowel between the attracting objects. Reported complications include perforation, volvulus, ulceration, and peritonitis. These patients therefore require a more vigilant follow-up. The clinician should also be alert to the complication associated with two attracting magnets on either side of the nasal septum. This situation can permanently damage the septum and therefore requires an urgent consult with the otolaryngologist.

AIM:

The purpose of this guideline is to establish a standard in the work-up and management of children with ingested foreign bodies. The aim is to reduce the morbidity associated with delayed diagnosis in these patients.

INCLUSION CRITERIA:

- 1) Stable children suspected of foreign body ingestion

EXCLUSION CRITERIA:

- 1) Secondary airway compromise from upper GI impaction necessitating immediate removal of the ingested object
- 2) Clinically unstable children with decreased level of consciousness, airway compromise, respiratory failure (abnormalities of oxygenation and ventilation), and/or shock

KEY POINTS:

- 1) All children with a history of foreign body ingestion should undergo radiographic evaluation.
- 2) Asymptomatic esophageal foreign bodies require 24 hours of observation in a hospital with continuous pulse oximetry. Presence of symptoms, sharp or long objects, or lack of progress within 24 hours warrant endoscopic removal under general anaesthesia.
- 3) ***Disc batteries in the esophagus must be removed urgently.***
- 4) Beyond the esophagus, most objects traverse the GI tract without complications. Long or sharp objects proximal to duodenal sweep are sometimes removed endoscopically, if possible. Long and sharp objects beyond the duodenal sweep require radiographic follow-up to ensure transit. If no progression is noted for weeks, then removal is considered by general surgery. If complications such as perforation ensue, then laparotomy is performed by general surgery.

- 5) Radiolucent objects require direct visualization or contrast radiographs for location specification.
- 6) Magnets when co-ingested with another magnet or metal object require a more vigilant follow-up.

FIGURE 1: Note the double contour appearance of a disc battery on a foreign body radiograph

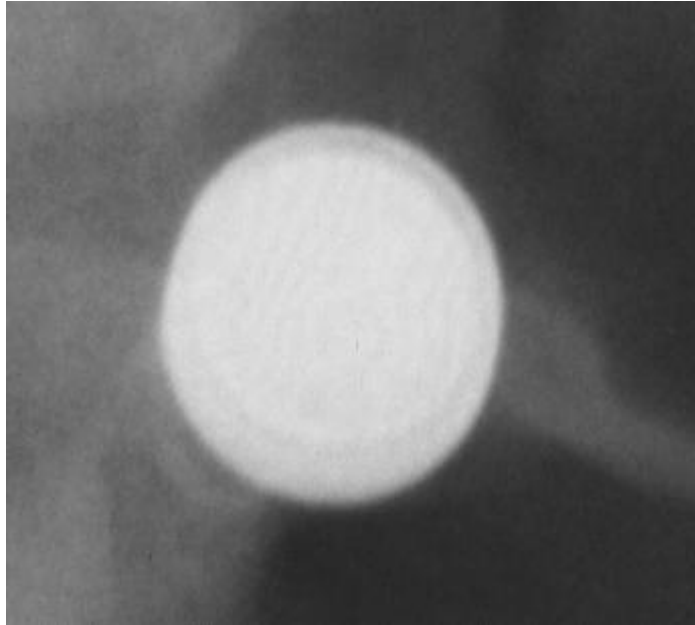
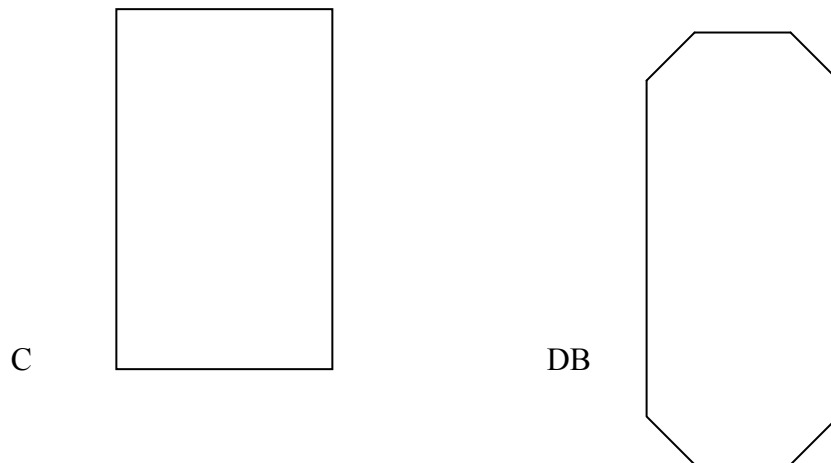


FIGURE 2: Note the schematic presentation of lateral appearances of a Coin (C) versus that of a Disc Battery (DB)



Suspected Foreign Body Ingestions in a clinically stable child

NOTE: See attached sheets for revised flow charts.

History and/or Signs and Symptoms of Foreign Body Ingestion ^{1 2 3}

Foreign Body Series (X-rays of neck, chest and abdomen)

Object in Esophagus

Object distal to esophagus

Object not seen

Mild (or no) symptoms ¹ & blunt object & ingestion < 24 hours

Sharp object or disc battery or inability to swallow secretions or stridor or pneumo-mediastinum

Moderate or severe symptoms ² or ingestion > 24 hours

-Observe up to 24 hours with continuous pulse oximetry ⁵
-Repeat x-rays (or evaluate with metal detector)
-Rigid endoscopy ⁶ if no progress in 24 hours

Urgent removal by rigid endoscopy and warn ICU

Removal by rigid endoscopy

Asymptomatic

Symptomatic ³

Removal via laparotomy by pediatric surgery

Go to radiolucent algorithm

Small blunt object

Large object ⁴

Sharp object

Weekly x-rays
Check stool

Beyond duodenal sweep

Proximal to duodenal sweep

Beyond duodenal sweep

Consider remove by endoscopy if still in stomach for > 1 week

Consider removal by pediatric surgery (laparotomy) if no progression for > 1 week after object is beyond stomach

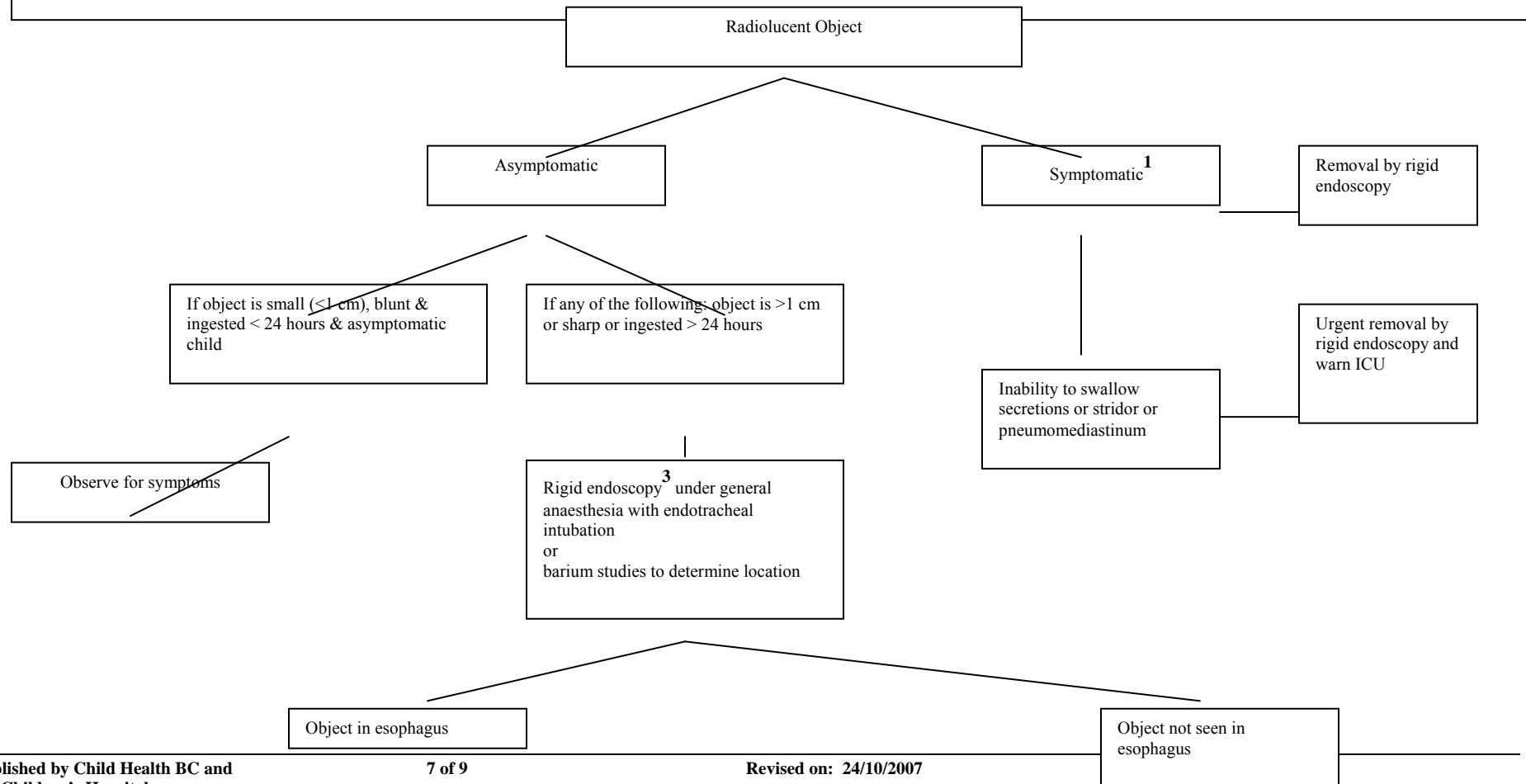
2007

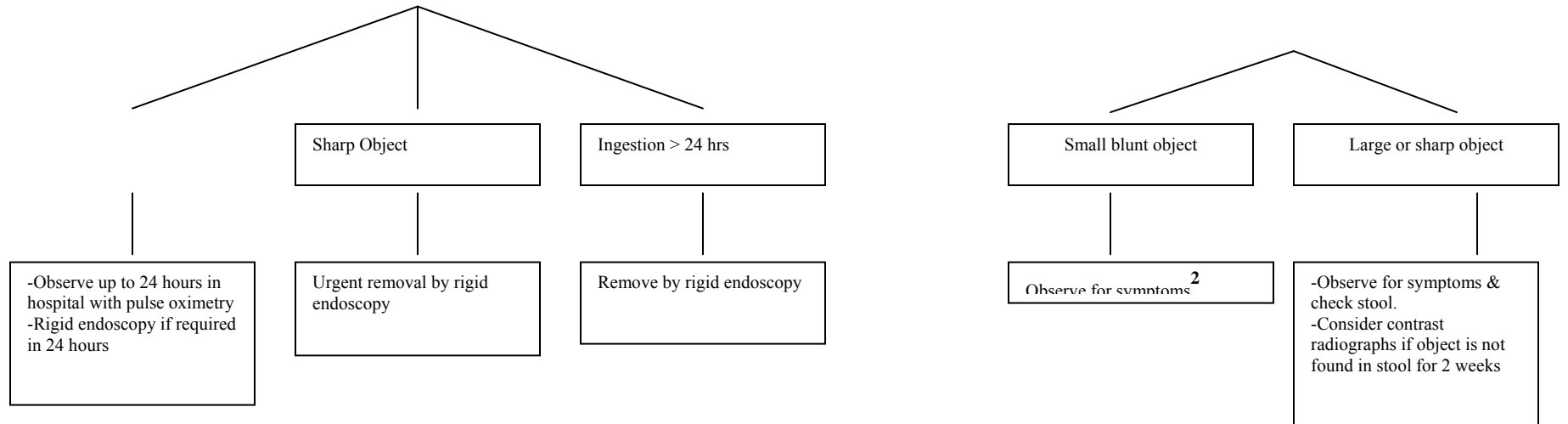
Remove by endoscopy if it can be done safely

Q3 daily x-rays and check stool

Consider removal by pediatric surgery (laparotomy) if no progression in > 3 days

- 1) Mild symptoms include refusal to eat, cough, nausea/vomiting, sore throat, foreign body sensation
- 2) Moderate or severe symptoms include dysphagia, odynophagia, drooling, stridor, or retrosternal pain.
- 3) Symptoms distal to the esophagus include hematochezia, melena, abdominal pain, or distension.
- 4) Large object : $\geq 2\text{-}3$ cm in children less than 1 year of age or $\geq 3\text{-}5$ cm in children over 1 year of age
- 5) Continuous pulse oximetry is required in case of a 'pop-up' of the foreign body into larynx.
- 6) Rigid endoscopy should be performed by a pediatric otolaryngologist or pediatric surgery. Laparotomy should be performed by pediatric surgery.





- 1) Symptoms include dysphagia, odynophagia, drooling, refusal to eat, foreign body sensation, nausea/vomiting, sore throat, cough, or retrosternal pain.
- 2) Hematochezia, melena, abdominal pain, or distension
- 3) Endoscopy should be performed by a pediatric otolaryngologist or pediatric surgery. Laparotomy should be performed by pediatric surgery.

REFERENCES:

Arana A, Hauser B, Hachimi-Idrissi S, et al. Management of ingested foreign bodies in childhood and review of the literature. *Eur J Pediatr*. 2001;160:468-72.

Cheng W and Tam PKH. Foreign-Body Ingestion in Children: Experience with 1265 Cases. *J Pediatr Surg* 1999;34:1472-6.

Eisen GM, Baron TH, Dominitz JA et al. Guideline for the Management of Ingested Foreign Bodies. *Gastrointest. Endosc.* 2002;55:802-6.

Ludemann JP, Hughes CA, Holinger LD. Management of Foreign Bodies of the Airway. In: Shields TW, LoCicero J, Ponn RB, editors. *General thoracic surgery*. Vol. 1. 5th ed. Philadelphia: Lippincott Williams and Wilkins; 2000. p. 853-862.

Schunk JE. Foreign Body – Ingestion/Aspiration. In: Fleisher GR, Ludwig S, Henretig FM, editors. *Textbook of Pediatric Emergency Medicine*. 5th ed. Philadelphia: Lippincott Williams and Wilkins; 2006. p. 307-314.

Wahbeh G, Wyllie R, Kay M. Foreign Body Ingestion in Infants and Children: Location, Location, Location. *Clin Pediatr*. 2002;41:633-640.

Waltzman M. Management of Esophageal Coins. *Pediatric Emergency Care*. 2006;22:367-373.

Uyemura MC. Foreign Body Ingestion in Children. *American Family Physician*. 2005;72(2):287-291.

Centers for Disease control and Prevention. Gastrointestinal injuries from magnet ingestion in children – United States, 2003-2006. *Morb Mortal Wkly Rep* 2006 Dec 8; 55: 1296-300.

ACKNOWLEDGEMENT: I would like to thank Mrs. Nadya Taylor, the administrator to the Division of Emergency Medicine, for assisting with the flowchart diagram.