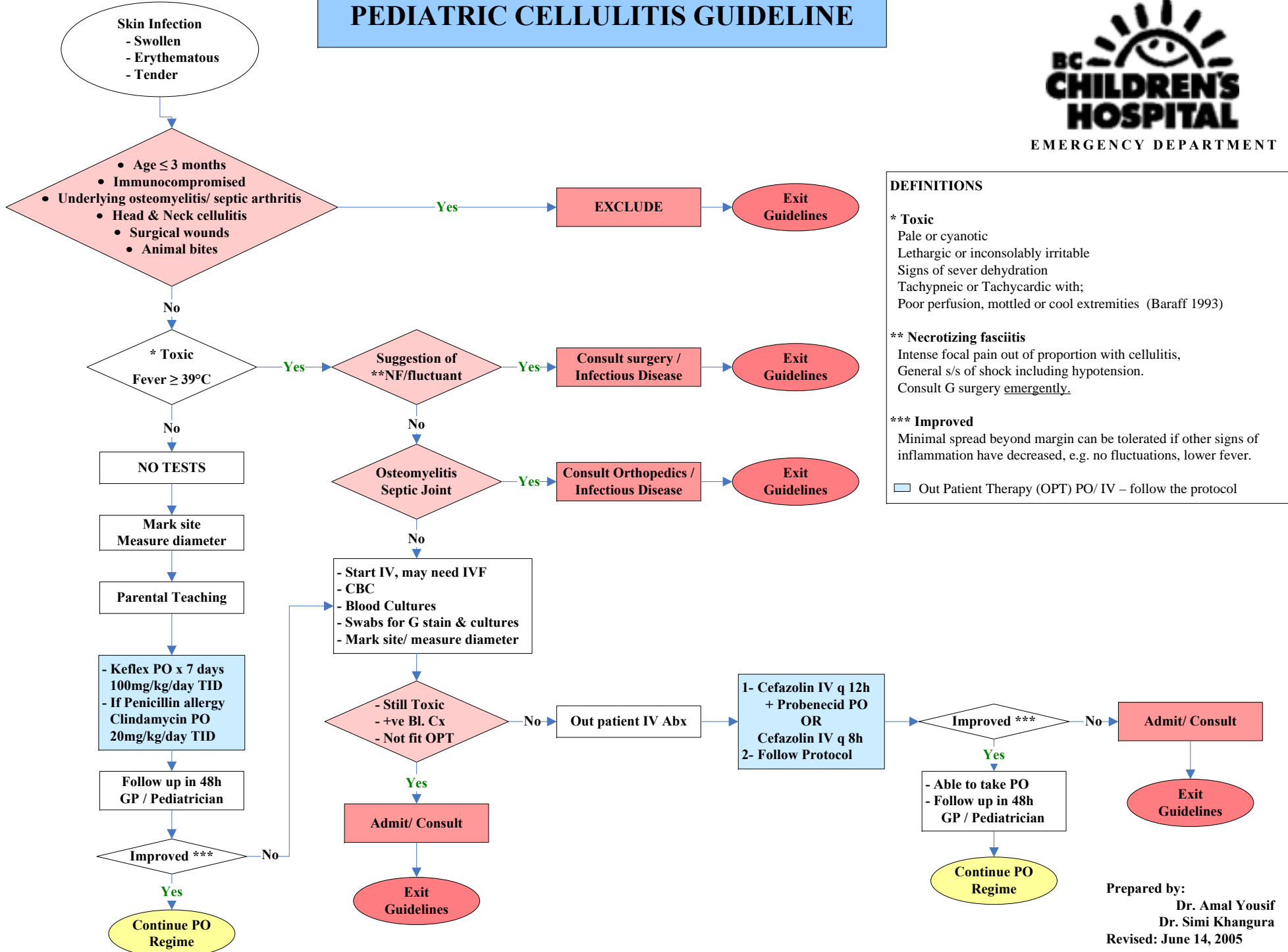


PEDIATRIC CELLULITIS GUIDELINE



DEFINITIONS

* Toxic

Pale or cyanotic
Lethargic or inconsolably irritable
Signs of severe dehydration
Tachypneic or Tachycardic with;
Poor perfusion, mottled or cool extremities (Baraff 1993)

** Necrotizing fasciitis

Intense focal pain out of proportion with cellulitis,
General s/s of shock including hypotension.
Consult G surgery emergently.

*** Improved

Minimal spread beyond margin can be tolerated if other signs of inflammation have decreased, e.g. no fluctuations, lower fever.

☐ Out Patient Therapy (OPT) PO/ IV – follow the protocol

Prepared by:
Dr. Amal Yousif
Dr. Simi Khangura
Revised: June 14, 2005